

Subarachnoid Hemorrhage as a Manifestation of Magic Mushroom Abuse: A Case Report and Review Literature

Hossein Mozhdehipanah¹ , Reza Gorji^{1*} 

¹ MD, Assistant Professor, Department of Neurology, Bu-Ali Sina Hospital, Qazvin University of Medical Sciences, Qazvin, Iran

* **Corresponding author:** Reza Gorji, Department of Neurology, Bu-Ali Sina Hospital, Qazvin University of Medical Sciences, Qazvin, Iran. Tel: +989122828530; Email: rezagorgi65@yahoo.com, reza.gorji@yahoo.com

Article Info	ABSTRACT
Article type: Case Report	Background: Psilocybin mushroom, which is worldwide famous as magic mushroom, is a relatively well-characterized hallucinogen manifesting a diverse dose-dependently spectrum of effects on healthy humans. As psilocybin has been increasingly abused among the youth, this research aimed to review the effects of the psilocybin administration, which is considered as either a good or bad trip among the consumers.
Article History: Received: 07 March 2021 Revised: 10 March 2021 Accepted: 13 March 2021	Case Report: This research reported a 20-year-old man who presented with severe thunderclap headache and consequent subarachnoid hemorrhage as a result of magic mushroom consumption.
Keywords: Headache Psilocybin Subarachnoid hemorrhage	Conclusion: The neurologic presentation of psilocybin could be various, which might lead to emergent situations as subarachnoid hemorrhage, and the notion of the harmlessness of magic mushroom was called into question.

➤ How to cite this paper

Mozhdehipanah H, Gorji R. Subarachnoid Hemorrhage as a Manifestation of Magic Mushroom Abuse: A Case Report and Review Literature. J Vessel Circ. Summer 2020; 1(3): 40-42. DOI: [10.29252/jvesselcirc.1.3.40](https://doi.org/10.29252/jvesselcirc.1.3.40)

Introduction

Psilocybin mushrooms, known as magic mushrooms or shrooms, are classified as a polyphyletic group of fungi containing psychedelic compounds, such as psilocybin, psilocin, and baeocystin. The popularization of psilocin as a new substance for abuse was evinced worldwide by Valentina Pavlovna Wasson in early 1970 (1, 2).

Psilocybin effects appear over 20 min which mostly include nausea, vomiting, muscle weakness, cognitive and emotional changes lasting up to 6 h based on individuals' metabolism in which the mind-altering effects could be even longer up to 8 h (3). Additionally, psilocybin is considered as a hallucinogen product altering the subjective experience of time as a result of interaction with cognitive dimensions of temporal processing via 5-HT_{2A} receptor stimulation. There are also reports of visual, auditory, and sensory hallucinations; feelings of detachment; inability to discern fantasy from reality; spiritual experiences; and panic reactions. Notably, drug-induced psychosis could

persist beyond the acute period in which the patient experiences flashbacks of previous perception impairment (3-6).

Similar to other psychedelics as lysergic acid diethylamide, the experience or trip can be positive or negative as an unpleasant experience, predominantly in higher dosages (4, 5).

This study aimed to describe a rare manifestation of magic mushroom, which is usually seen with amphetamine drugs, focusing on a 20-year-old man presenting with thunderclap headache as a result of subarachnoid hemorrhage (SAH) following magic mushroom abuse.

Case Report

The patient was a 20-year-old man with no significant medical history referring to the emergency department with an episode of thunderclap headache. The subject reported the consumption of an unknown quantity of mushroom in the form of tea for the first time at a party 4 h

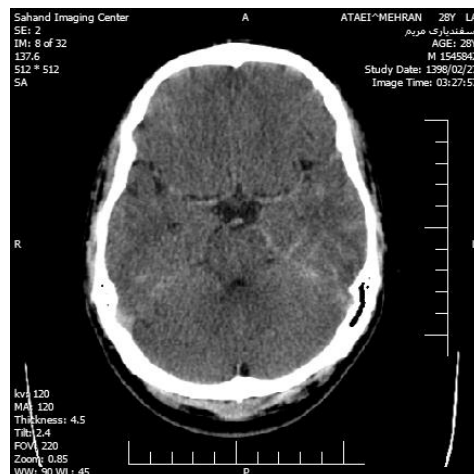
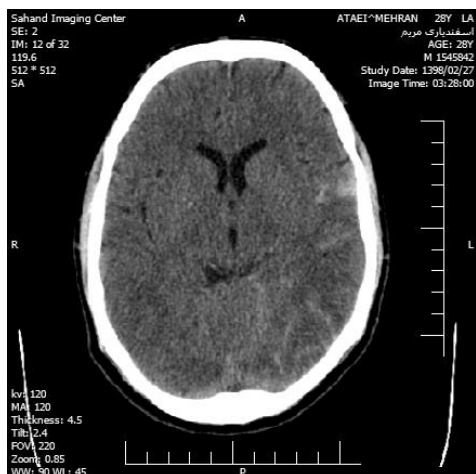


Figure 1. Evidence of parietal, temporal, and occipital cortical subarachnoid hemorrhage (mostly on the left side) and a thin rim in left perimesencephalic cistern subarachnoid hemorrhage without intraventricular hemorrhage

before admission. He noticed the strange feeling of extraordinary spiritual ability to soul summoning. Following the fantasy, theosophical ceremony, and visual hallucination of the soul summoned, suddenly he suffered a severe thunderclap headache accompanied by nausea and vomiting leading to his referral to our emergency department.

On examination, he was conscious and oriented; however, he had disorganized thought and delusion of considerable mystical ability. The vital sign evaluation revealed a blood pressure of 185/110 mmHg, pulse rate of 90, the temperature of 37°C, and respiratory rate of 16. No evidence of meningeal signs was obtained, and other systemic and neurologic assessments were unremarkable.

The patient underwent brain computed tomography (CT) without contrast, which revealed subarachnoid hemorrhage along the parietal, temporal, occipital convexities without evidence of intraventricular hemorrhage or hydrocephalus (Figure 1).

The patient was admitted to the intensive care unit and subjected to standard medical treatment. Intravenous labetalol was used to control blood pressure. The laboratory findings were all within normal limits. Subsequently, the patient underwent CT angiography which was unrevealing. Brain magnetic resonance imaging did not show a more considerable finding than the brain CT.

The neurosurgery and clinical toxicology consult were requested, which all suggested conservative treatment. In the next days, the patient improved gradually with no complaint of headache and disorganized thought. The controlled brain imaging revealed the resolution of the hemorrhage. Taking into account all considerations, the patient was diagnosed with SAH associated with magic mushroom abuse. The patient was transferred to the neurology ward and discharged with a good general condition and normal physical examination.

Discussion

Psilocybin mushroom is a potentially illegal substance belonging to a subclass of hallucinogens. Historical evidence suggests the consumption of psilocybin mushrooms in ancient religious rites and ceremonies over 7,000 to 9,000 years ago, which is still one of the most recreational psychedelics in the United States and Europe (6). Brande reported the hallucinogenic effect of mushrooms for the first time in 1799 and described a family who served *Psilocybe semilanceata* mushrooms for breakfast leading to an uncontrollable laugh in one of the members of the family (7).

In the 1960s, psilocybin mushroom was adopted in the counterculture and soon was listed as an illegal drug in 1971. Currently, they are the most commonly used psychedelics among the youth. Based on the results of a survey conducted by Hallock et al. (2012), 30 % of the participants had tried mushrooms at least once (8).

A typical trip on a moderate dose of magic mushroom (1-2.5 g) comprises a dreamy state accompanied by perceptual, emotional change, and distorted sense of time. Furthermore, such side effects as vital sign instability, nausea and vomiting, tremor, and increased tendon reflexes have been reported (3-6).

The correlation between headache and magic mushroom administration is controversial. There are reports of psilocybin-induced migraine-like headache, as the double-blind study conducted by Johnson et al, which disclosed headache as an adverse event of non-medical exposure with psilocybin. On the other hand, a few preclinical trials are suggesting a promising role of psilocybin in the treatment of cluster headache (9-11). Psilocybin increases the expression of several genes, including $I\kappa B-\alpha$, the main inhibitor of $NF\kappa B$. Expression of

inducible nitric oxide synthase enhancing NO release is dependent on NF κ B, which is directly suppressed by psilocybin. Nonetheless, there is no convincing evidence to confirm this hypothesis as the main mechanism of headache induced by psilocybin. In addition, psilocybin might trigger headache through an increase in brainstem serotonergic activities via influence on 5-HT_{1A}, D, 5-HT_{2A}, C, 5-HT₅, 5-HT₆, and 5-HT₇ receptor (12, 13).

On the other hand, SAH is a rare type of cerebrovascular accident, which is mainly aneurysmal and accounts for 5% of strokes occurring at a relatively young age. Compared to other cerebrovascular accidents, SAH has a poorer outcome. The overall mortality rate ranges from 32%-67% with 10%-20% of patients with long-term dependence due to brain damage. Regarding the increasing rate of stroke-related deaths and disability-adjusted life years, compared to all diseases, the early diagnosis and consequent appropriate treatment are of paramount importance and special attention should be dedicated toward SAH associated with drug abuse (14-16).

To the best of our knowledge, there is no report of subarachnoid hemorrhage as a consequence of psilocybin in the literature. Our research is the first report of subarachnoid hemorrhage induced by psilocybin products.

Conclusion

Our report is unique as it highlights the diversity of neurologic side effects of this common substance. This research focused on subarachnoid hemorrhage as a rare manifestation of psilocybin.

Conflict of interest

The authors declare that they have no conflict of interests.

References

- Guzmán G. Hallucinogenic mushrooms in Mexico: an overview. *Econ Bot* 2008;62(3):404-12. DOI: 10.1007/s12231-008-9033-8
- Rush JA. Entheogens and the development of culture: the anthropology and neurobiology of ecstatic experience. Berkeley, California: North Atlantic Books; 2013. P. 488. [Link](#)
- Carter OL, Burr DC, Pettigrew JD, Wallis GM, Hasler F, Vollenweider FX. Using psilocybin to investigate the relationship between attention, working memory, and the serotonin 1A and 2A receptors. *J Cogn Neurosci* 2005; 17(10):1497-508. DOI: 10.1162/089892905774597191
- Samorini G. The oldest representations of hallucinogenic mushrooms in the world (Sahara Desert, 9000-7000 BP). *Integration* 1992;2(3):69-78. [Link](#)
- Studerus E, Komater M, Hasler F, Vollenweider FX. Acute, subacute and long-term subjective effects of psilocybin in healthy humans: a pooled analysis of experimental studies. *J Psychopharmacol* 2011;25(11):1434-52. DOI: 10.1177/0269881110382466
- Passie T, Seifert J, Schneider U, Emrich HM. The pharmacology of psilocybin. *Addict Biol* 2002;7(4):357-64. DOI: 10.1080/1355621021000005937
- Brande E. Mr. E. Brande, on a poisonous species of agaric. *Med Phys J* 1800;3(11):41-4. [Link](#)
- Hallock RM, Dean A, Knecht ZA, Spencer J, Taverna EC. A survey of hallucinogenic mushroom use, factors related to usage, and perceptions of use among college students. *Drug Alcohol Depend* 2013;130(1-3):245-8. DOI: 10.1016/j.drugalcdep.2012.11.010
- Sewell RA, Halpern JH, Pope HGJ. Response of cluster headache to psilocybin and LSD. *Neurology* 2006;66(12):1920-2. DOI: 10.1212/01.wnl.0000219761.05466.43
- Schindler EA, Gottschalk CH, Weil MJ, Shapiro RE, Wright DA, Sewell RA. Indoleamine hallucinogens in cluster headache: results of the clusterbusters medication use survey. *J Psychoactive Drugs* 2015;47(5):372-81. DOI: 10.1080/02791072.2015.1107664
- Johnson MW, Sewell RA, Griffiths RR. Psilocybin dose-dependently causes delayed, transient headaches in healthy volunteers. *Drug Alcohol Depend* 2012;123(1-3):132-40. DOI: 10.1016/j.drugalcdep.2011.10.029
- Czyrak A, Czepiel K, Mackowiak M, Chocyk A, Wedzony K. Serotonin 5-HT_{1A} receptors might control the output of cortical glutamatergic neurons in rat cingulate cortex. *Brain Res* 2003;989(1):42-51. DOI: 10.1016/s0006-8993(03)03352-3
- Gonzalez-Maeso J, Yuen T, Ebersole BJ, Wurmbach E, Lira A, Zhou M, et al. Transcriptome fingerprints distinguish hallucinogenic and nonhallucinogenic 5-hydroxytryptamine 2A receptor agonist effects in mouse somatosensory cortex. *J Neurosci* 2003;23(26):8836-43. DOI: 10.1523/JNEUROSCI.23-26-08836.2003
- Paybast S, Ashraf A, Sarshad H, Shakiba M, Moadabi Y. Propagating relationship of cerebral oximetric volume and the clinical outcome of recombinant tissue plasminogen activator (r-TPA) therapy on acute cerebral ischemic stroke patients. *Adv J Emerg Med* 2019;4(1):e7. DOI: 10.22114/ajem.v0i0.174
- Grasso G, Alafaci C, Macdonald RL. Management of aneurysmal subarachnoid hemorrhage: state of the art and future perspectives. *Surg Neurol Int* 2017;8:11. DOI: 10.4103/2152-7806.198738
- Aghamiri H, Paybast S, Lima BS, Mansoori B. New advances in acute ischemic stroke management. *Int Clin Neurosci J* 2020;7(2):55-60. [Link](#)